CORONARY ANATOMY

Dr. Angela Kealey, MD, FRCP(C)
Clinical Assistant Professor, University of Calgary
Libin Cardiovascular Institute

Disclosures

- **Faculty: Angela Kealey, MD, FRCP(C)**

- **Relationships with commercial interests:**
  - **Grants/Research Support:** NIH
  - **Speakers Bureau/Honoraria:** Pfizer, Servier

Objectives

- Epicardial coronary anatomy
- Coronary perfusion
- Physiology of exercise and pharmacological agents used for cardiac stress
- Balanced ischemia

Epicardial coronary anatomy

- Called coronary arteries (L. *corona*) because they circle the base of the ventricles like a crown
- Left and right coronary arteries are branches of the ascending aorta and usually arise from the left and right coronary sinuses

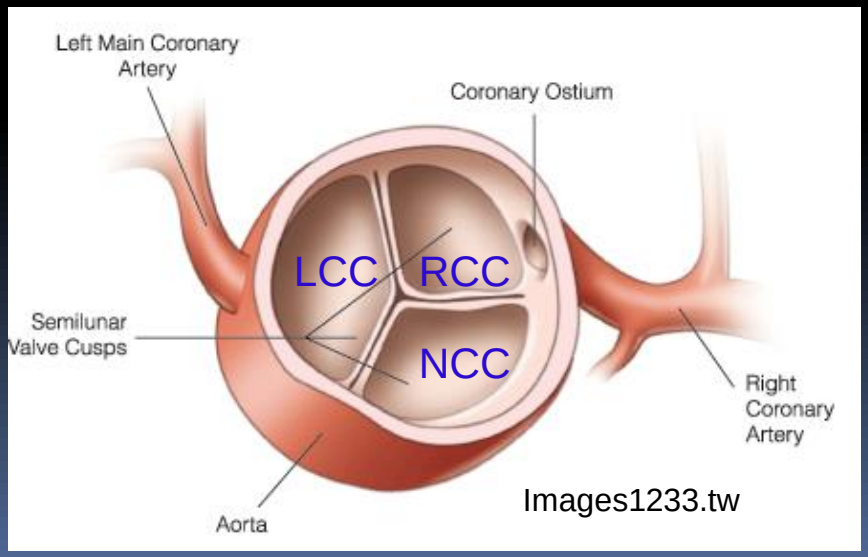

Left coronary artery

- Left main artery divides into the left anterior descending artery (LAD) and the left circumflex artery (LCx)
- Left circumflex supplies the lateral wall
  - Obtuse marginal branches
  - Posterolateral branches
  - Posterior descending artery (10%)

Left anterior descending artery

- Supplies the anterior, anterolateral and septal walls
  - Septal branches
  - Diagonal branches
- May or may not supply the apex
  - Type I – terminal LAD does not reach apex
  - Type II – terminal LAD reaches apex
  - Type III – terminal LAD wraps around the apex and supplies the distal inferior wall

Left coronary artery

Right coronary artery

Branch	Incidence
Sinuatrial node	55%
Right ventricular	~100%
Posterior descending	~90%
Atrioventricular node	85%
Posterolateral	~80%

Right coronary artery

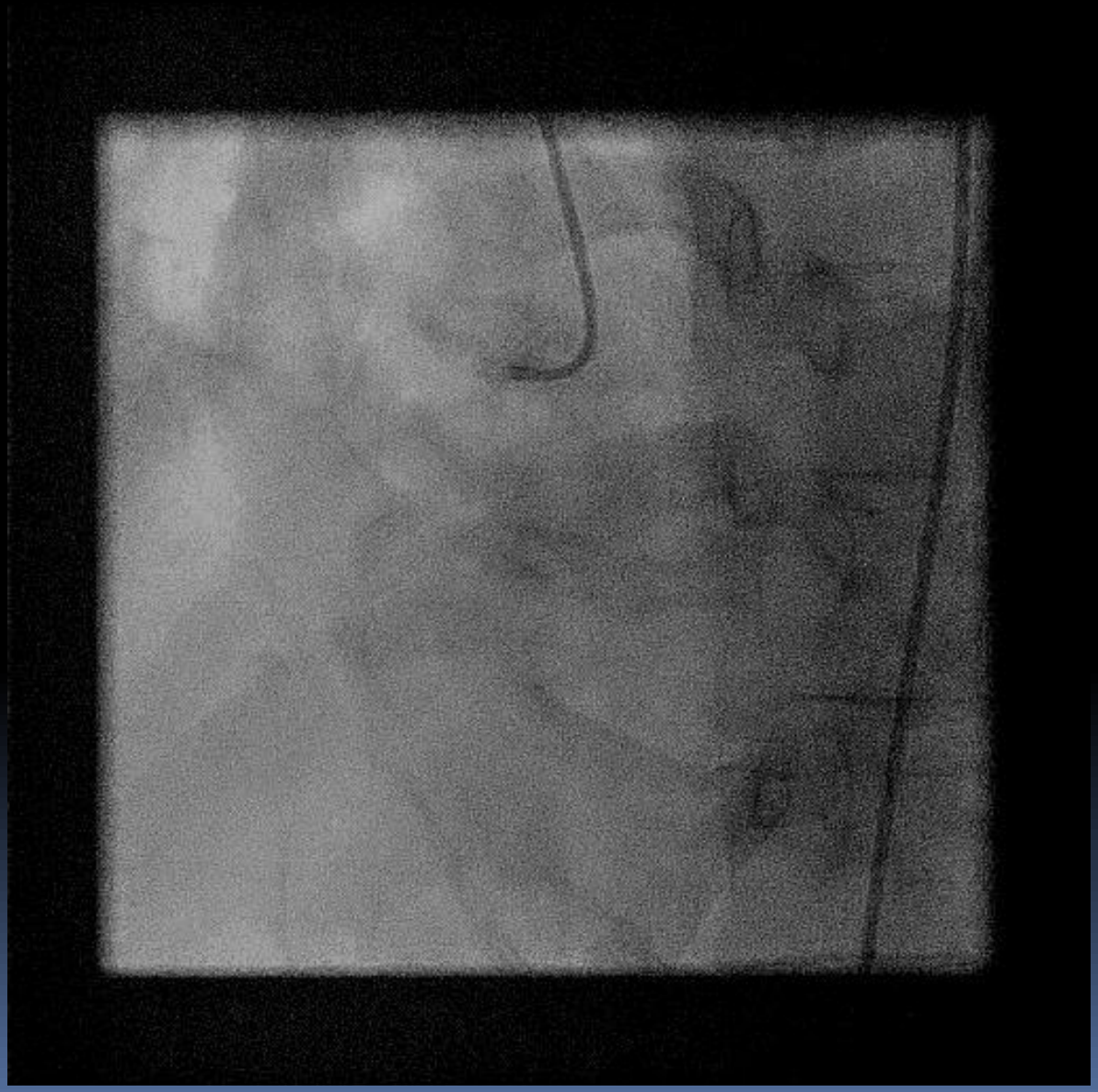

“Traditional” epicardial anatomy

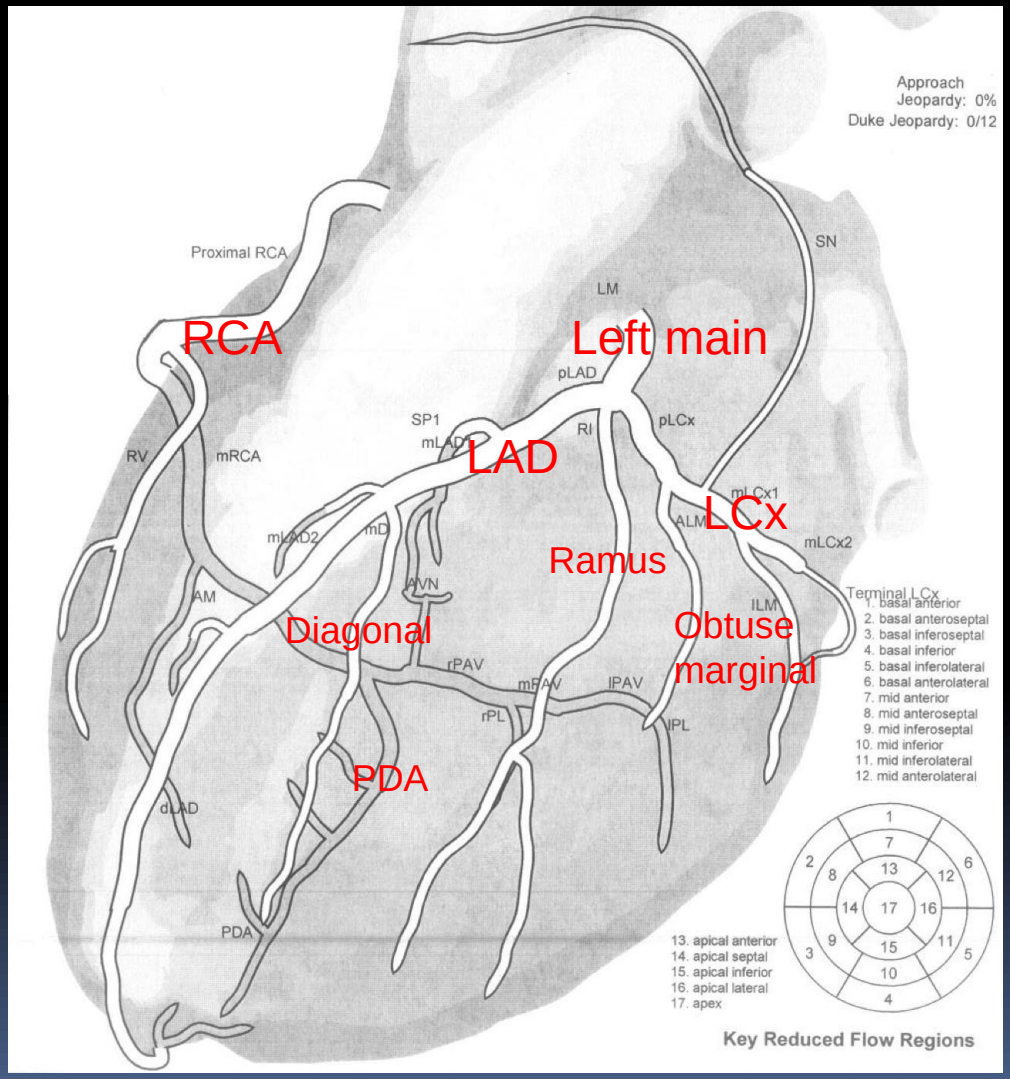

Coronary artery dominance

- A coronary artery is said to be dominant if it supplies the posterior descending artery and *at least* one posterolateral branch
  - Right dominant
  - Left dominant
  - Co-dominant

Coronary artery dominance

- Right coronary dominant (~70-85%)
  - Right coronary artery supplies the posterior descending artery and at least one posterolateral branch
- Left coronary dominant (~10-15%)
  - Left circumflex artery supplies all posterolateral branches and the posterior descending artery
- Co-dominant (~8-15%)
  - RCA supplies the PDA, LCx supplies all PLs

Why is this important?



Mishfish13.com

- Significant variation among the population
- Cannot assume that a certain territory is supplied by a specific artery

17-Segment model of the left ventricle

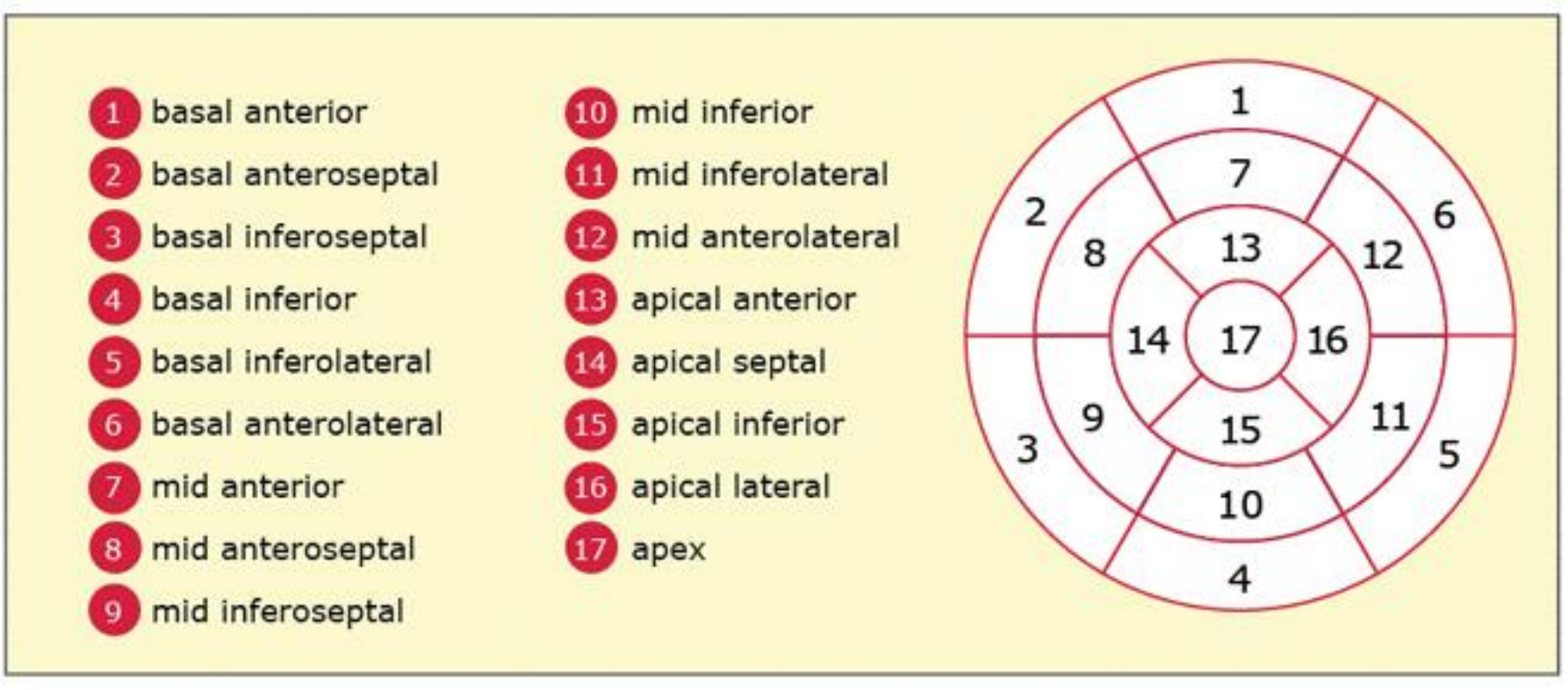

Adapted from the American Society of Nuclear Cardiology. J Nucl Cardiol.1999;6:G47-G84.2. Figure 2.

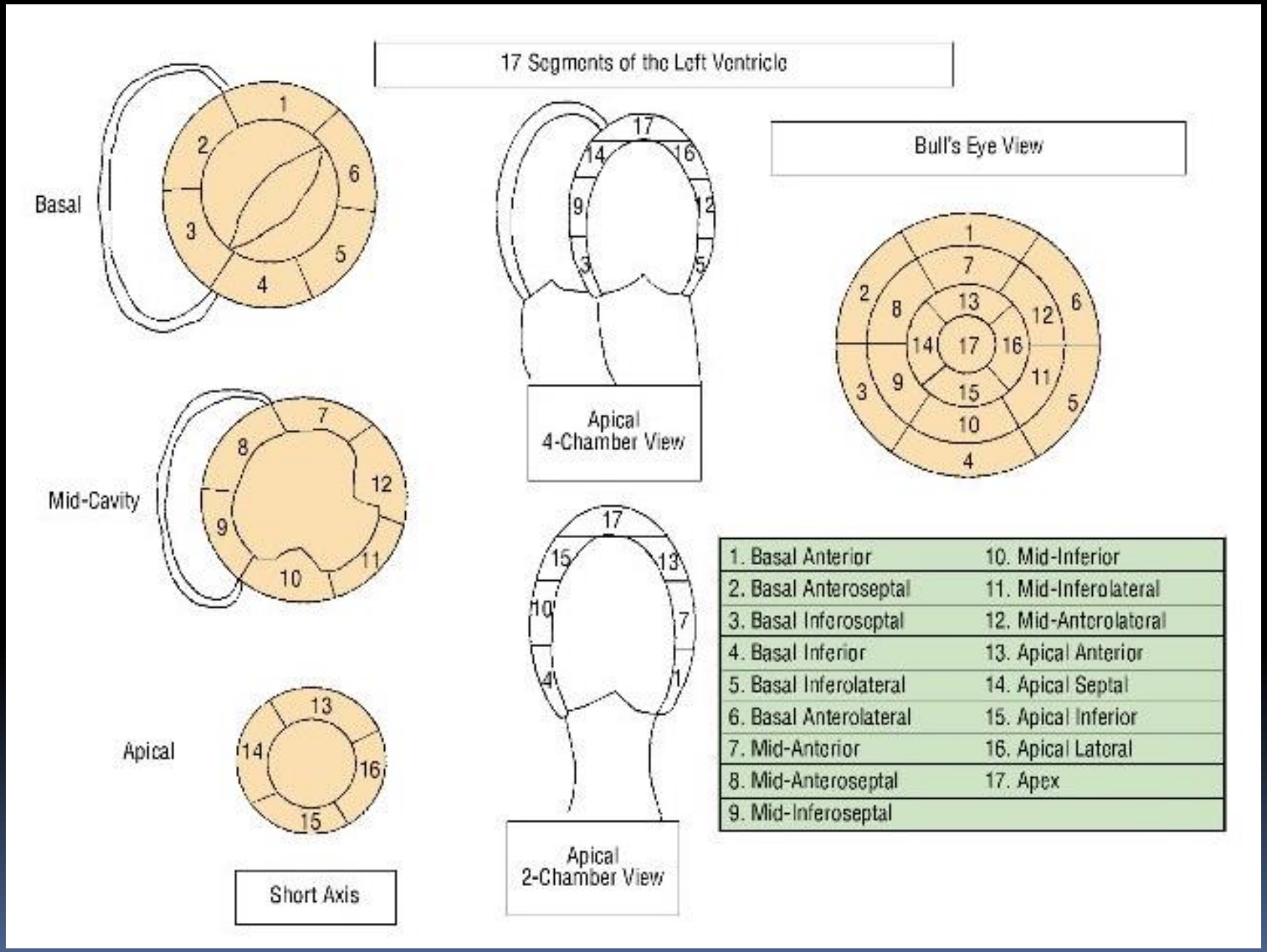
17 Segments of the Left Ventricle
Basal
Mid-Cavity
Apical
Short Axis
Apical 4-Chamber View
Apical 2-Chamber View
Bull's Eye View
1. Basal Anterior
2. Basal Anteroseptal
3. Basal Inferoseptal
4. Basal Inferior
5. Basal Inferolateral
6. Basal Anterolateral
7. Mid-Anterior
8. Mid-Anteroseptal
9. Mid-Inferoseptal
10. Mid-Inferior
11. Mid-Inferolateral
12. Mid-Anterolateral
13. Apical Anterior
14. Apical Septal
15. Apical Inferior
16. Apical Lateral
17. Apex

If we were all the same…

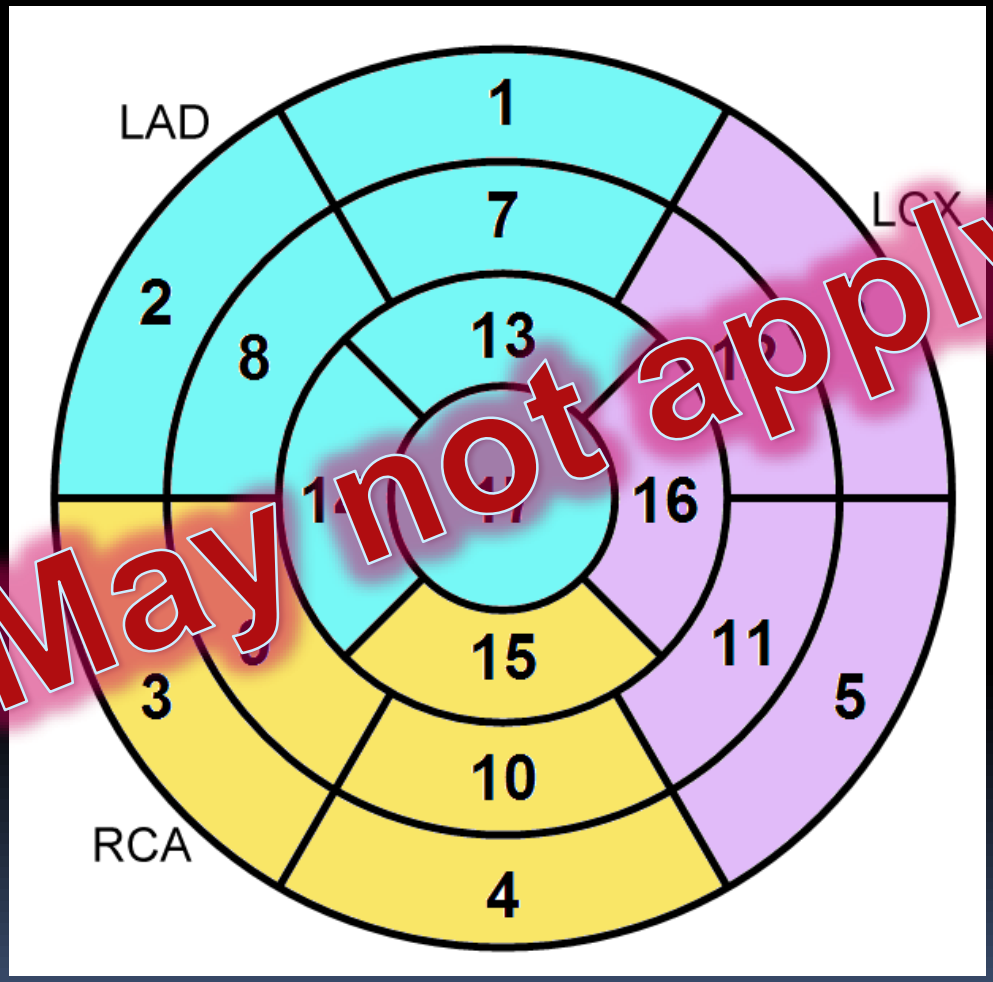

A Tale of Two LADs



A Tale of Two Cities by Charles Dickens

It was the best of times…

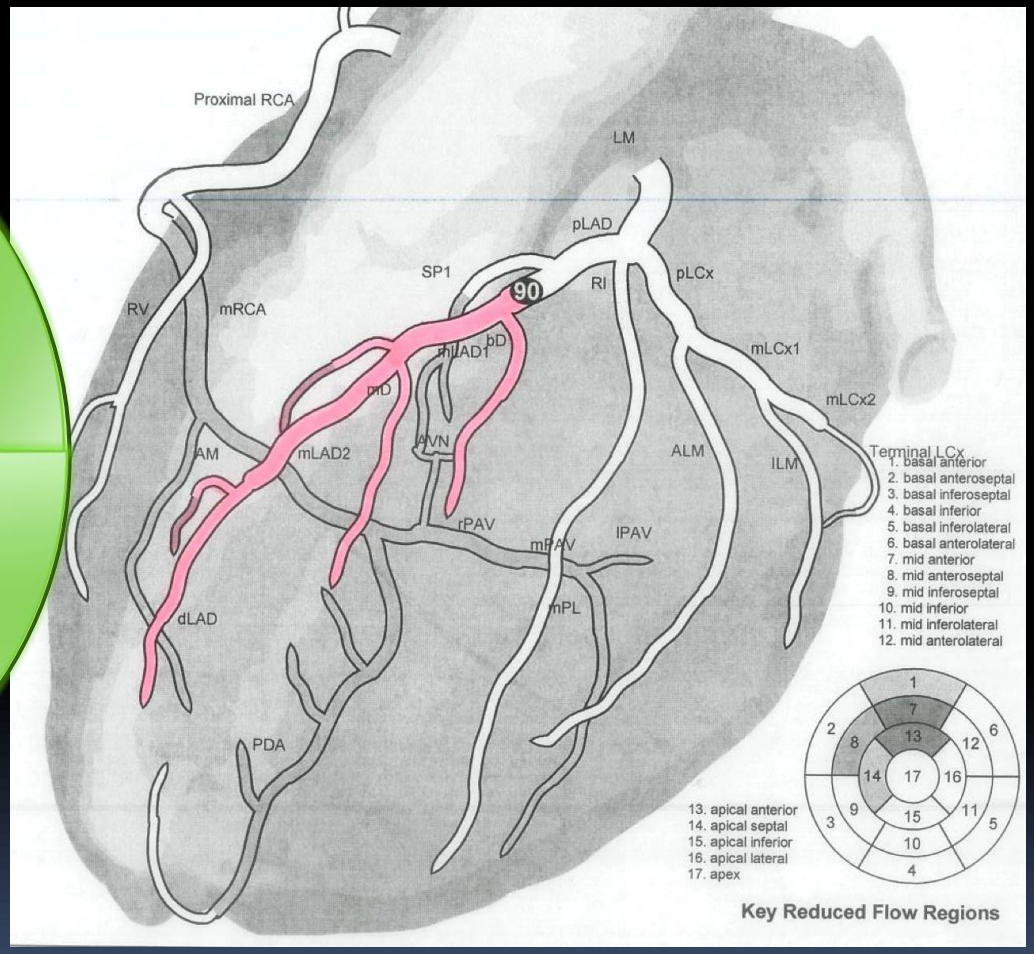

29% of myocardium affected

It was the worst of times…



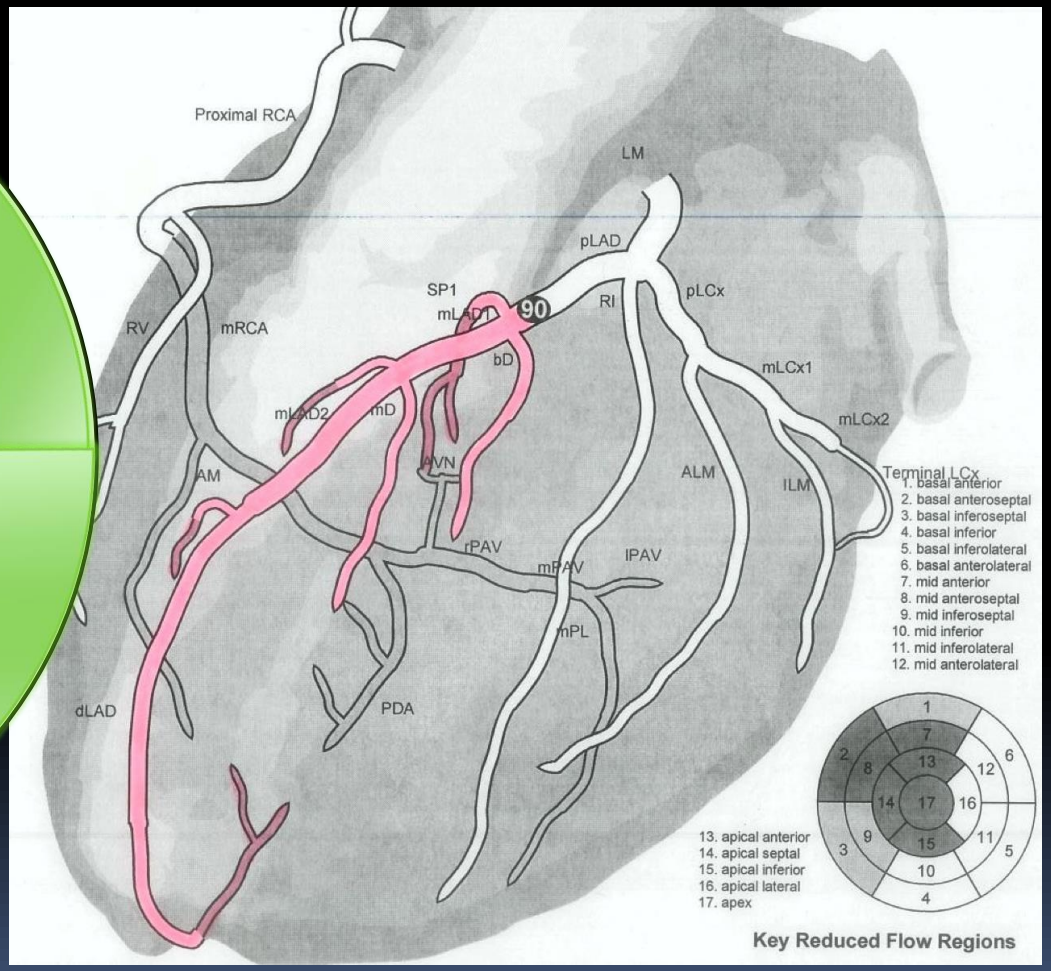

59% of myocardium affected

Non-dominant LCx



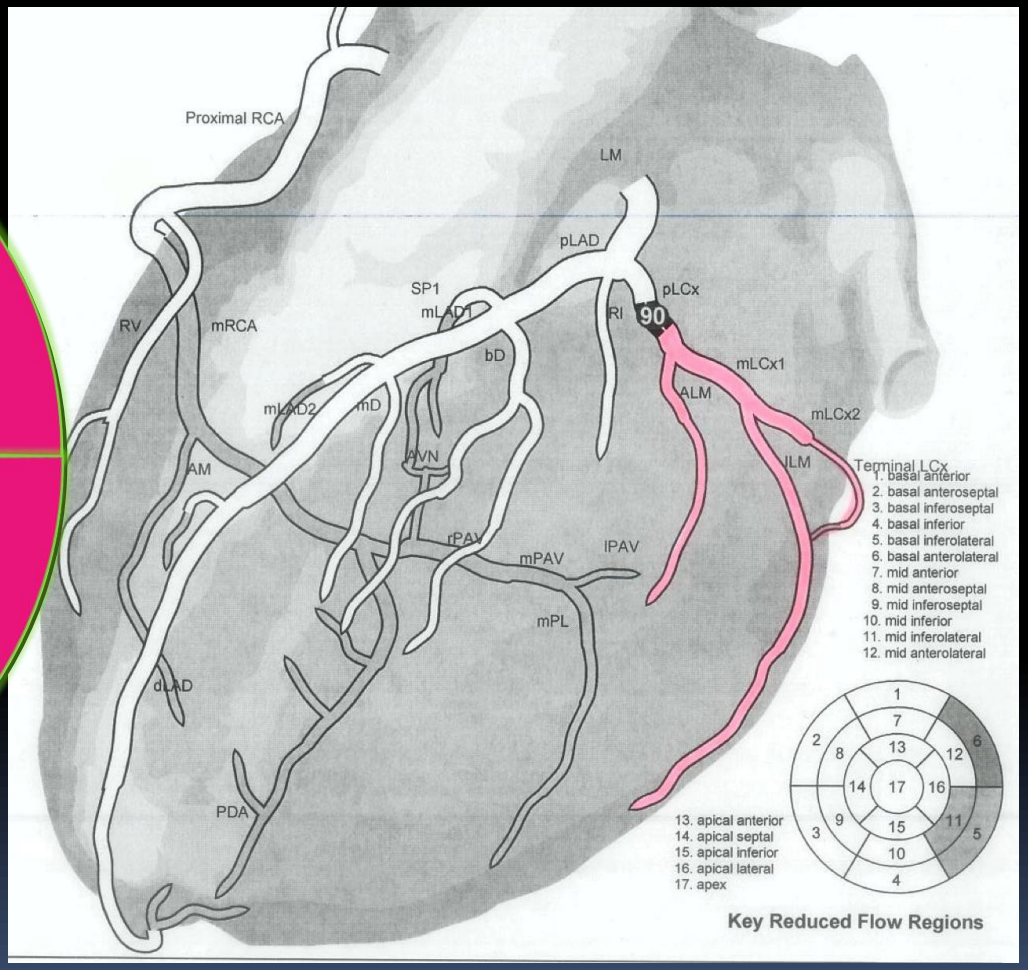

18% of myocardium affected

Dominant LCx



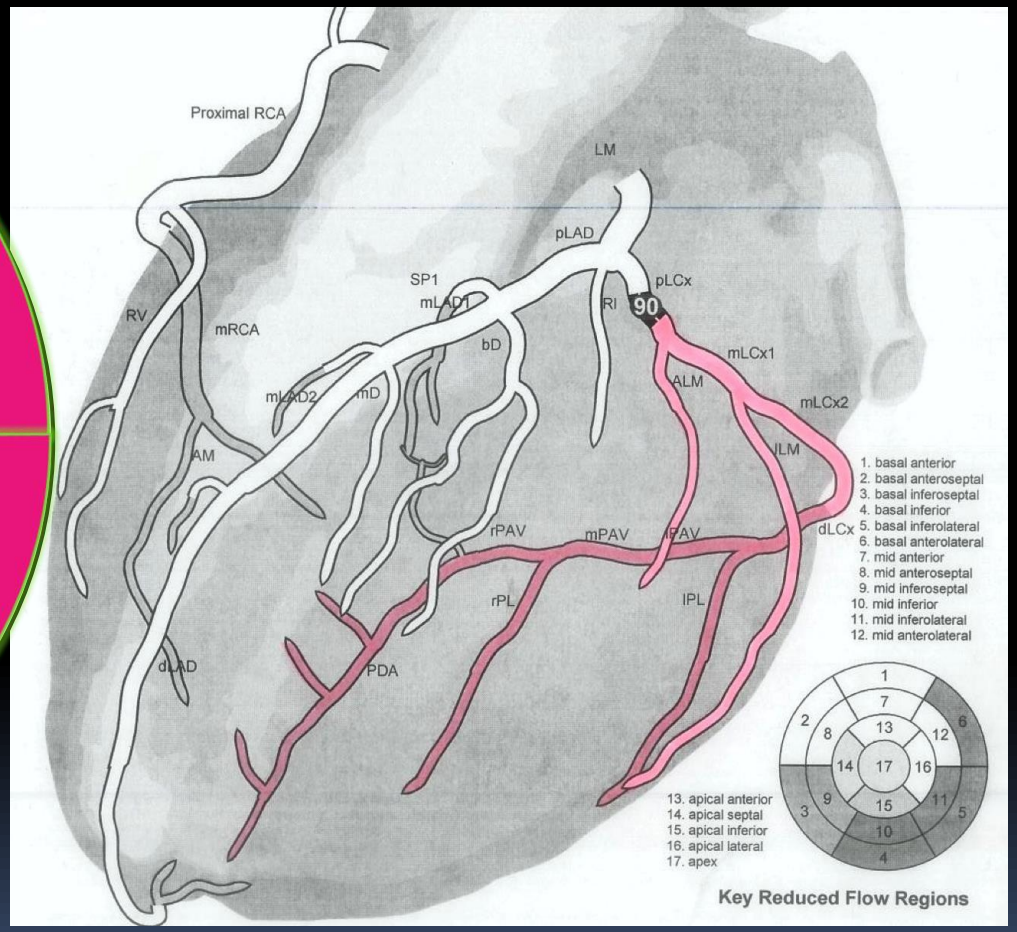

47% of myocardium affected

A particularly bad day…



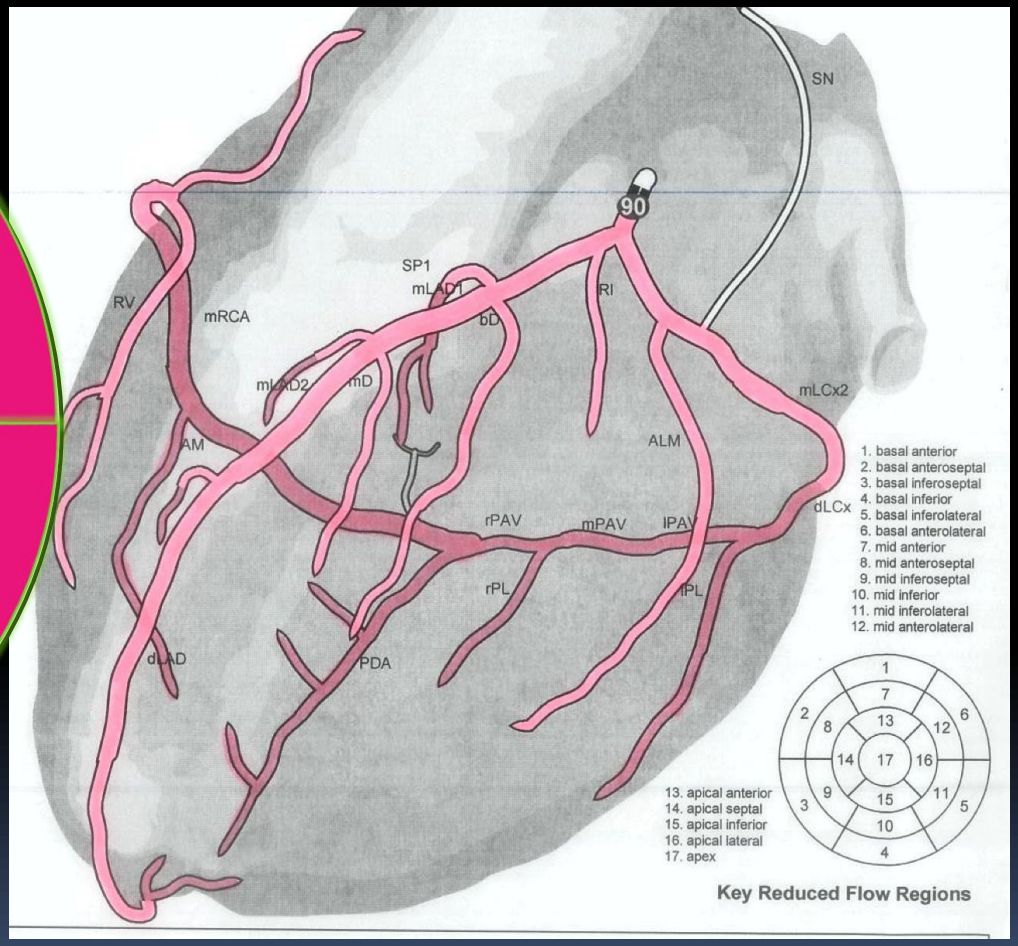

100% of myocardium affected

Anomolous coronary anatomy

- Incidence ~1%
  1. Separate ostia for LAD and LCx
  2. RCA originating in left coronary cusp
  3. LCA originating in right coronary cusp
  4. LCx originating in right coronary cusp with LAD coming from left coronary cusp or reverse
- Anomolous artery can go around the major vessels (good) or between the PA and aorta (bad)

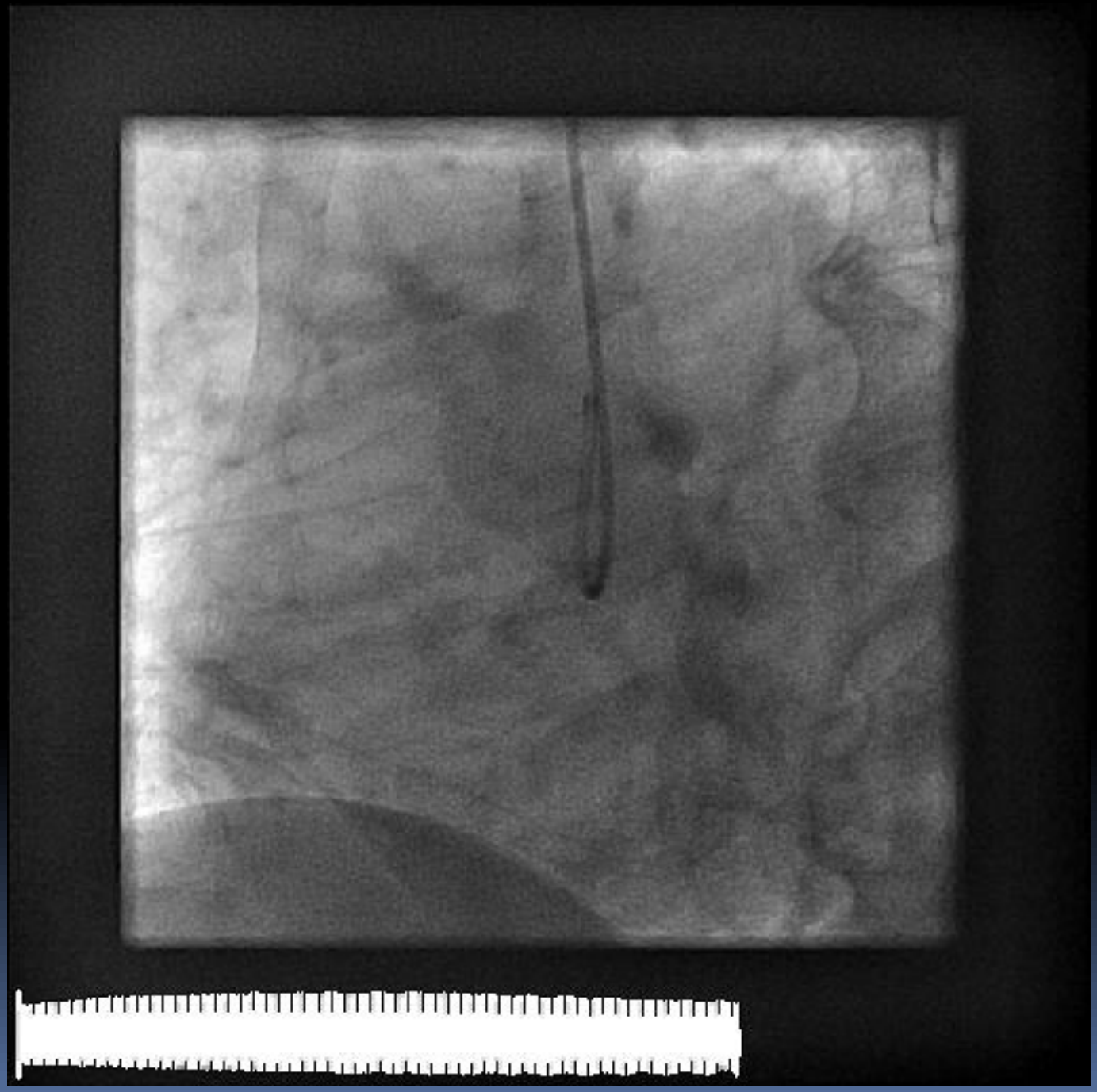

Further complicating our simplistic approach

- Collateral circulation – when there is stenosis or occlusion of an artery, arteriogenesis can occur whereby a "bypass" vessel can form to supply the affected territory
- Blood supply by collateral flow is variable – territory on imaging can appear infarcted, ischemic or normal depending on adequacy of collaterals

Epicardial coronary anatomy

- Significant variation among the population
- Consequences of a stenosis/occlusion in a specific artery are highly variable depending on the patient's anatomy
- Most important consideration is the volume of myocardium at risk

"The red circles are your red blood cells.
The white circles are your white blood cells.
The brown circles are donuts. We need to talk."

Coronary perfusion

- Resting coronary blood flow accounts for 5% of cardiac output
- Blood flow through the coronary system is regulated mostly by local arteriolar vasodilation in response to the nutritional needs of cardiac muscle

Coronary perfusion

- ↓oxygen concentration → vasodilator substances released → arteriole vasodilation

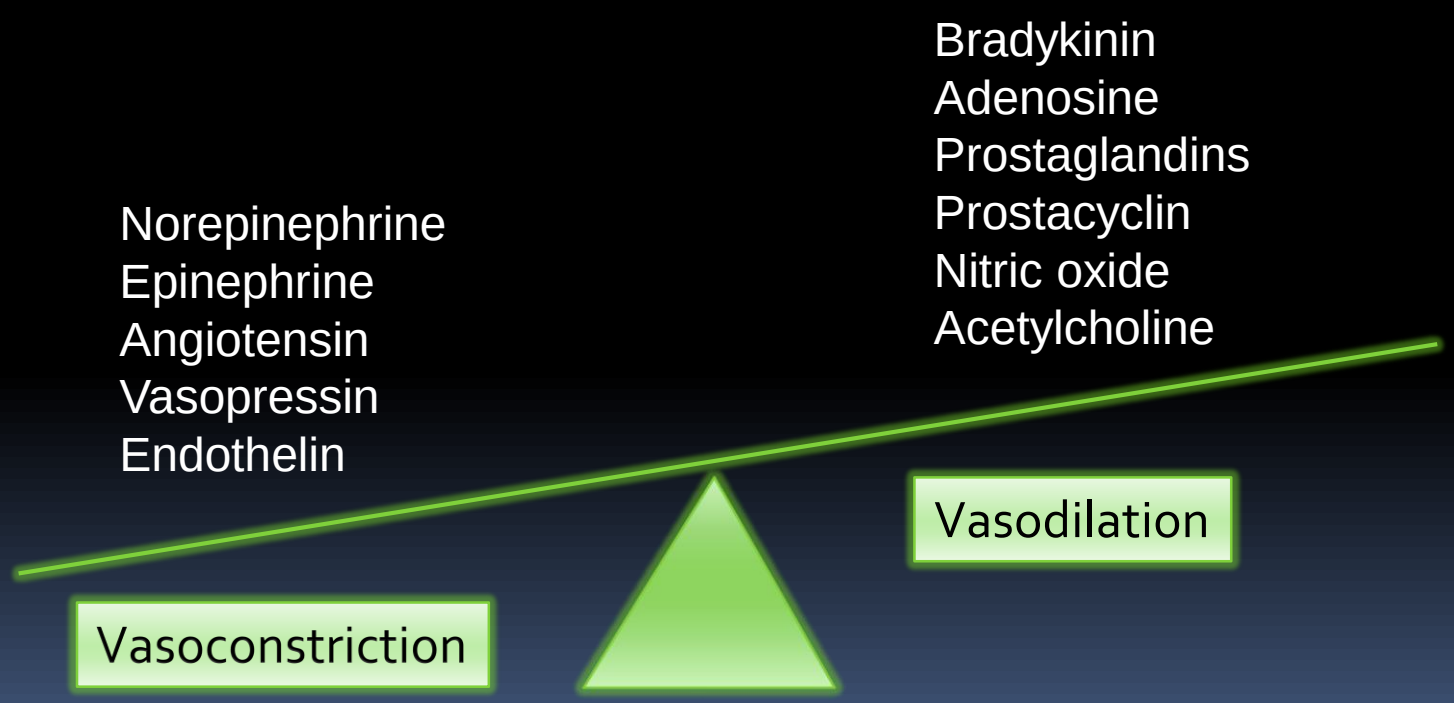

↓[O_2]

Good [O_2]

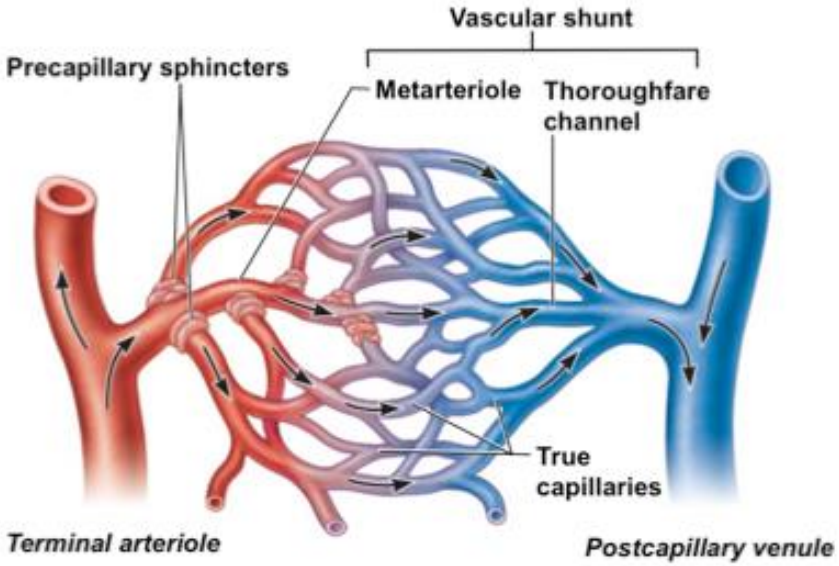

(a) Sphincters open—blood flows through true capillaries.

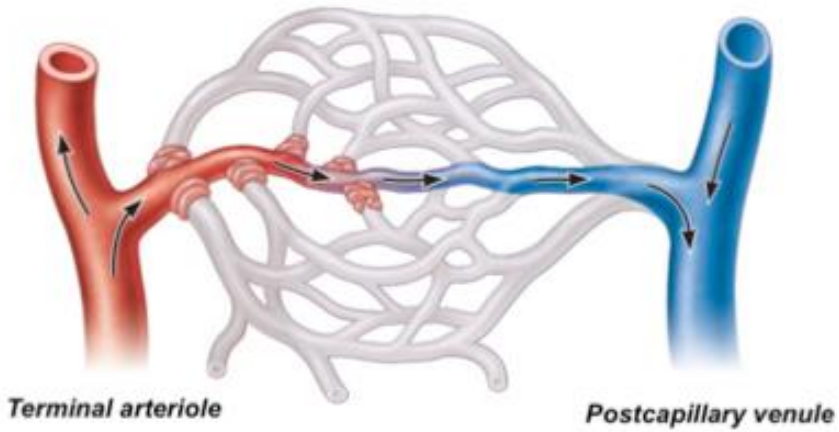

(b) Sphincters closed—blood flows through metarteriole – thoroughfare channel and bypasses true capillaries.

Physiology of exercise

- Exercising skeletal muscle requires increased blood flow to meet oxygen demand
- Cardiac output must increase
  - CO = Stroke volume x heart rate
  - ⇧ heart rate, contractility and ventricular work
  - ⇧ coronary perfusion to supply myocardium
- With exercise, coronary flow increases 3- to 4-fold, oxygen demands of the LV increase 6-fold

Pharmacological stress

- Used for patients who are unable to exercise to 85% of their age-predicted maximum heart rate
- Used for patients with LBBB or ventricular pacing
- Many different agents available

Pharmacological stress

- Vasodilators
  - Persantine – works by increasing intravascular adenosine levels; long duration of action; can't be used if bronchospasm
  - Adenosine – short acting
  - Preferred over catecholamines in wide QRS
- Catecholamines
  - Dobutamine – positive inotrope and chronotrope; mimics exercise

Coronary perfusion in a normal artery

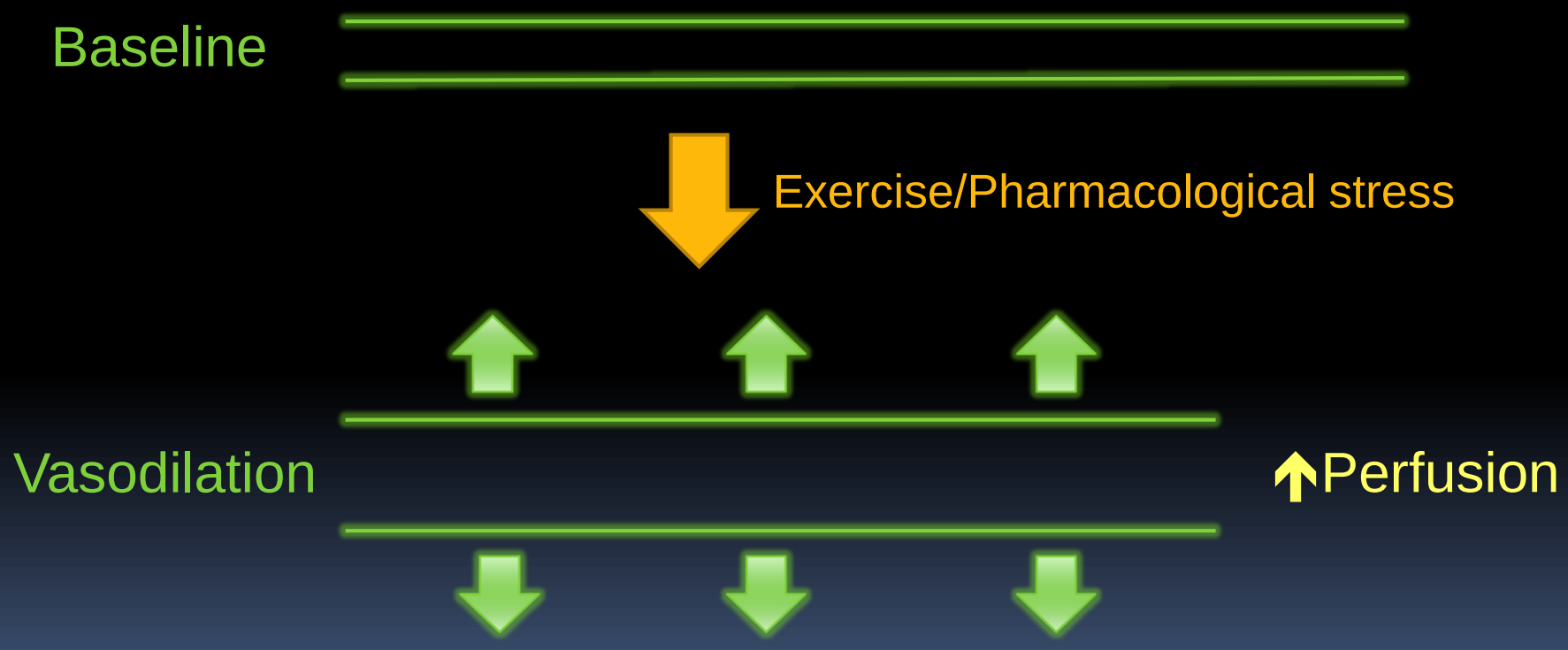

Coronary perfusion in a diseased artery

- When there is a hemodynamically significant coronary stenosis, the distal artery is maximally dilated at rest to improve distal blood flow
- Neither exercise nor exogenous vasodilators will cause further vasodilation of the distal vessel

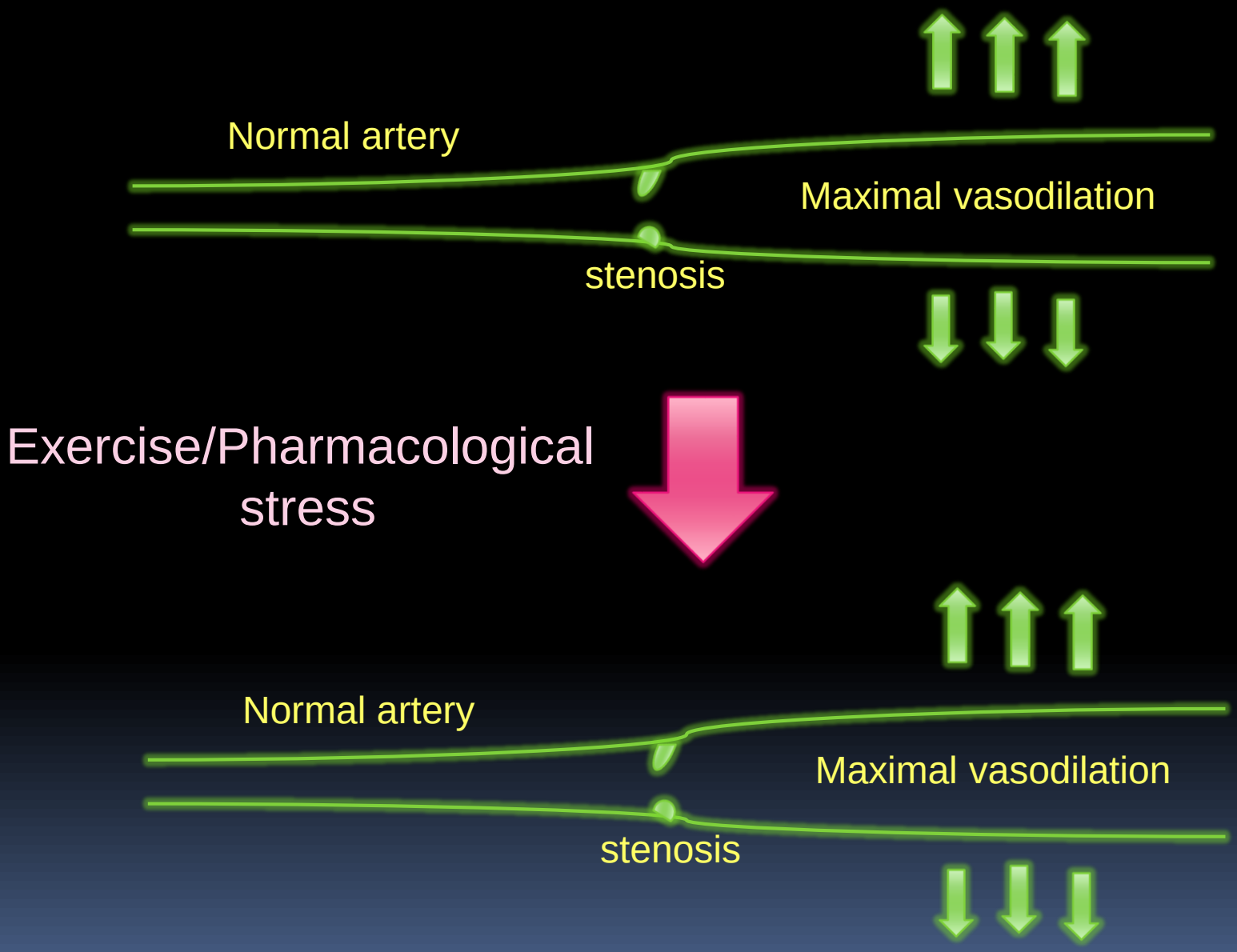
Normal artery
Maximal vasodilation
stenosis
Exercise/Pharmacological stress
Normal artery
Maximal vasodilation
stenosis

What does this mean for perfusion imaging?

Coronary perfusion – normal arteries

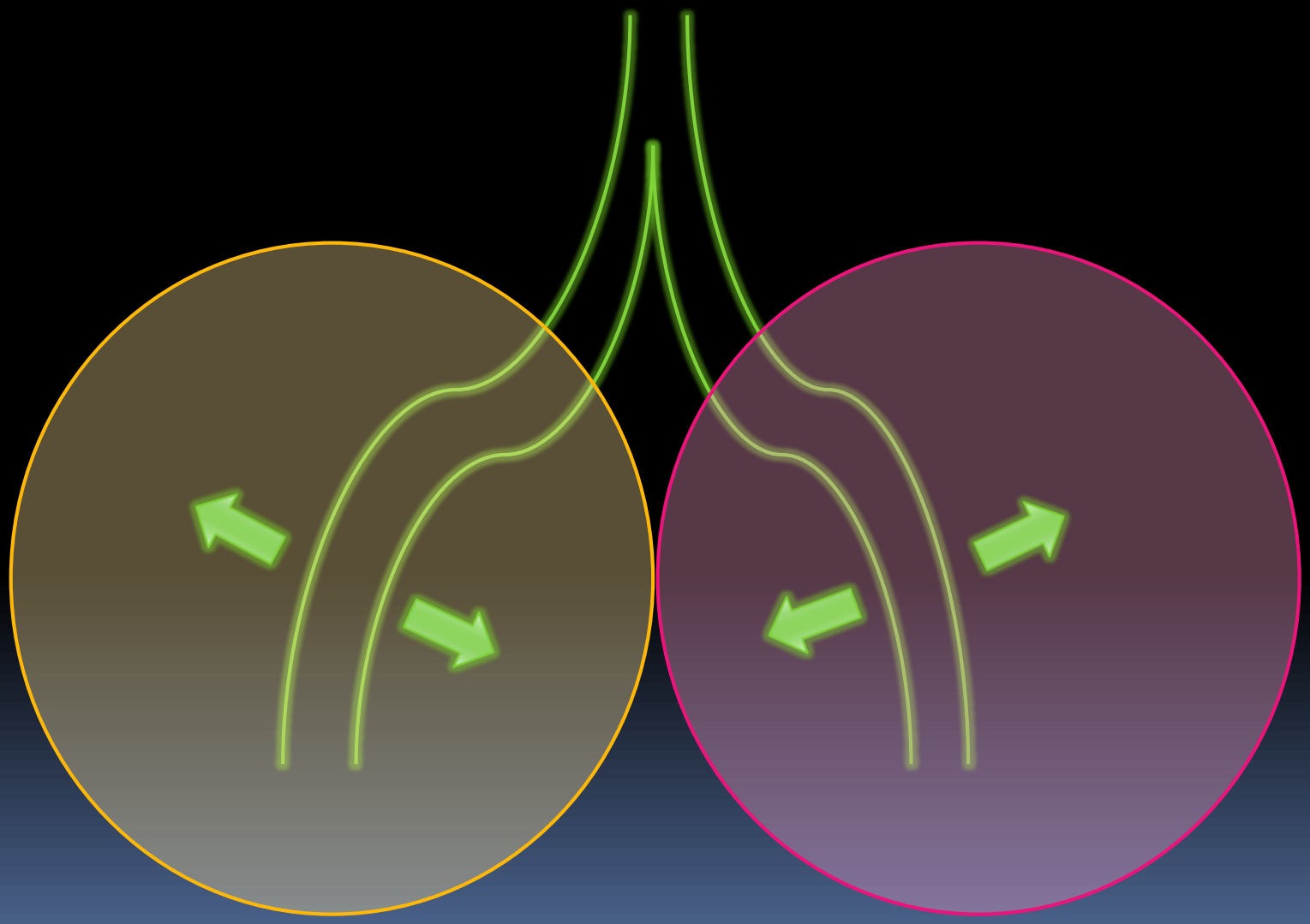

Coronary perfusion – single stenosis

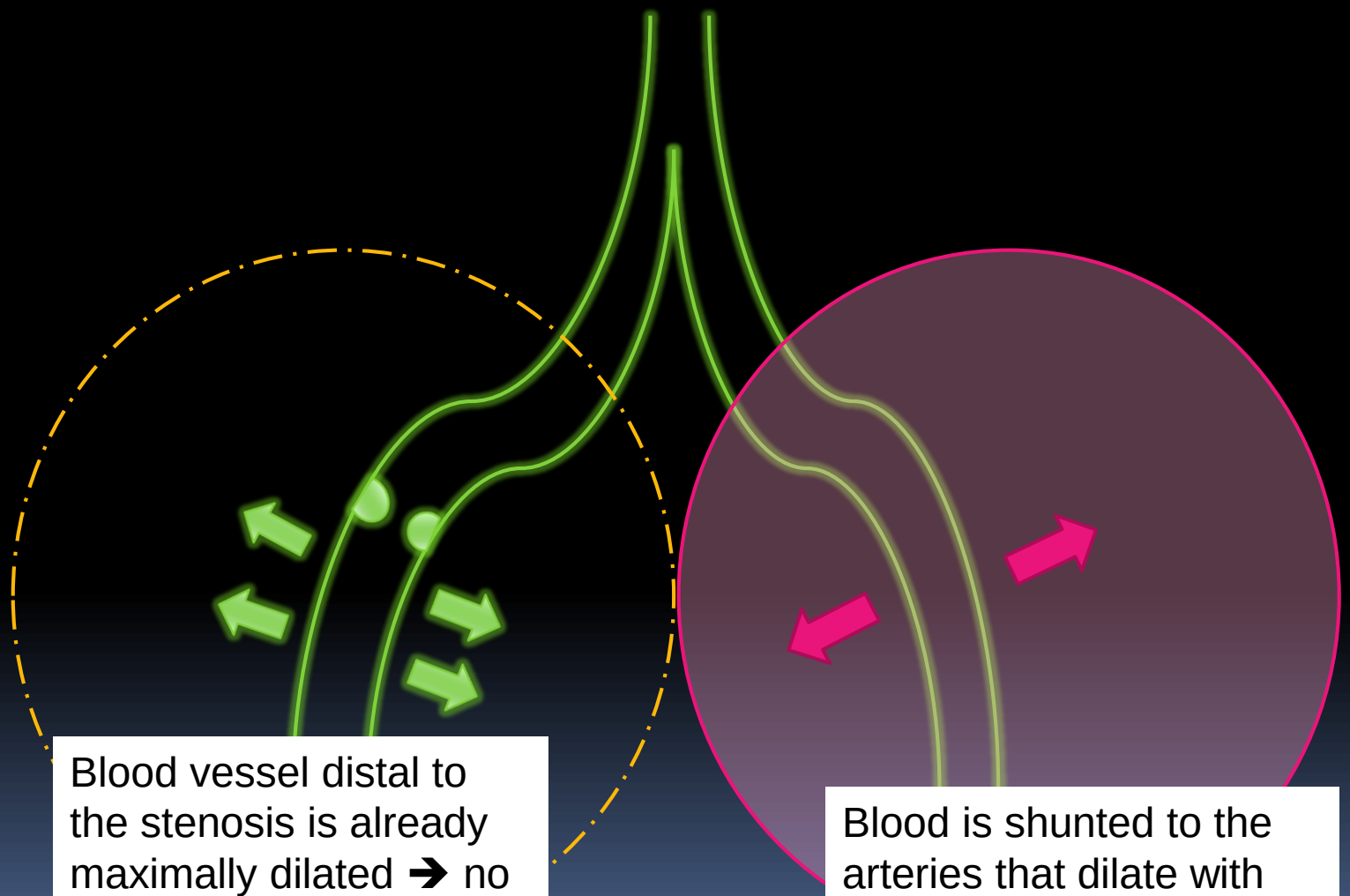

Blood vessel distal to the stenosis is already maximally dilated ➔ no increased blood flow

Blood is shunted to the arteries that dilate with stress

Coronary perfusion – stenoses in all branches

Balanced Ischemia

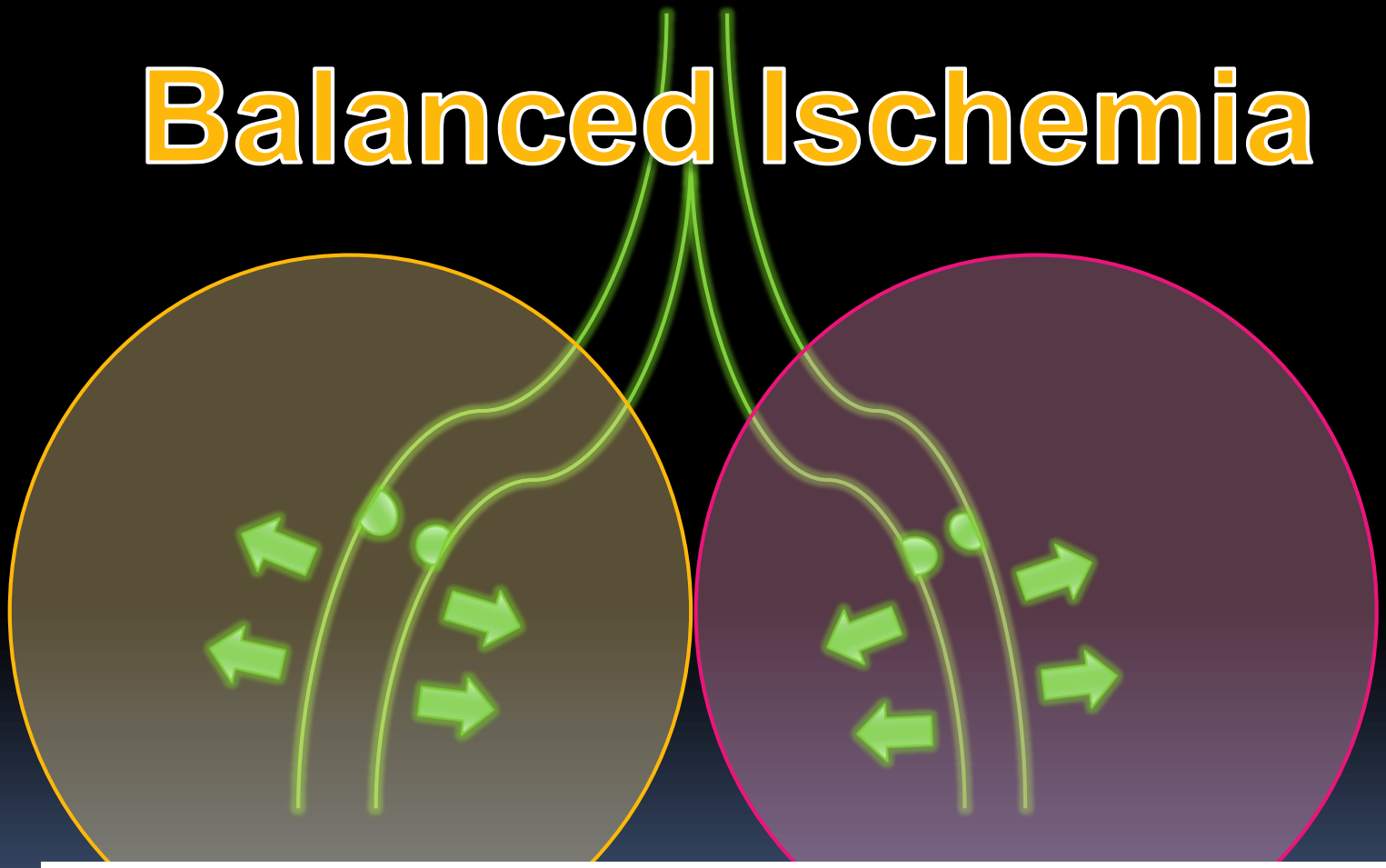

Both diseased arteries are maximally dilated ➔ no further dilation with stress ➔ blood is shunted equally to both territories

Coronary perfusion

- In order to identify an ischemic territory, there needs to be normal perfusion to at least one other territory
- If all territories are supplied by diseased vessels, all territories will be perfused equally
  - Balanced ischemia

Conclusions

- Significant variation in coronary anatomy among individuals
- Coronary perfusion is determined by the balance of local vasodilators and vasoconstrictors as well as by arterial lumen patency
- Myocardial perfusion testing relies on having one normally perfused territory to identify ischemia